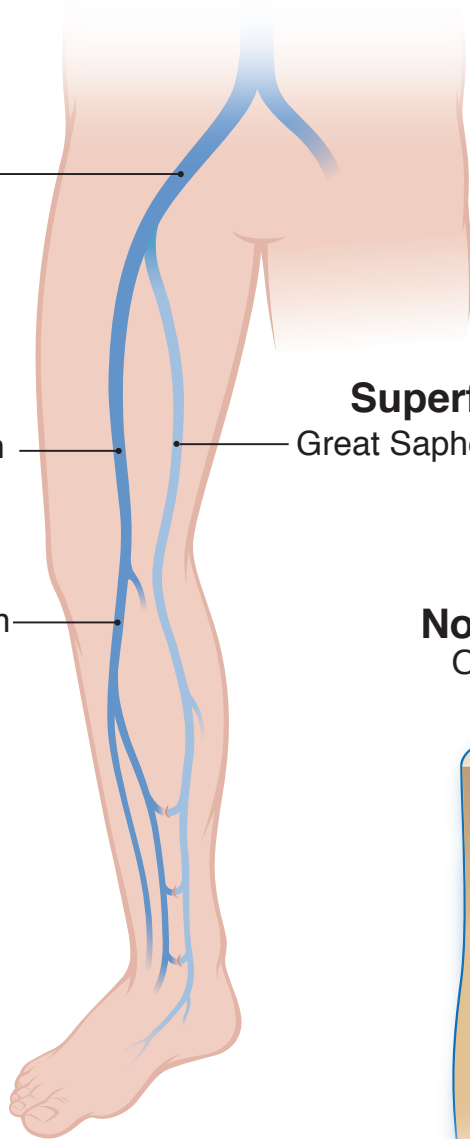


## Deep Veins:

Iliac Vein

Common Femoral Vein

Popliteal Vein




## Superficial Veins:

Great Saphenous Vein (GSV)

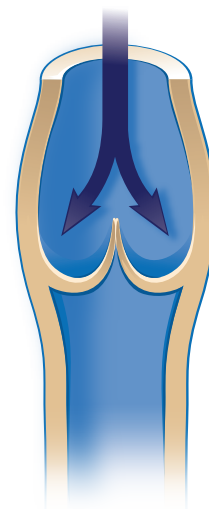# Venous Insufficiency

### Normal Vein Open Valve



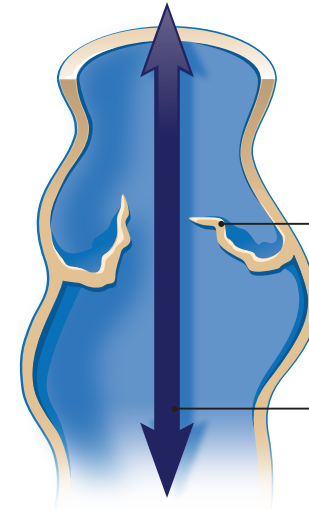
Normal valve opens to allow blood flow toward heart

### Normal Vein Closed Valve



Normal valve closes to prevent reverse of blood flow

### Varicose Vein Damaged/Nonfunctional Valve



Incompetent valve

Vein wall thinned and bulging

Abnormal blood flow backward down leg

Damaged/Nonfunctional valve cannot close properly and blood flow is impaired