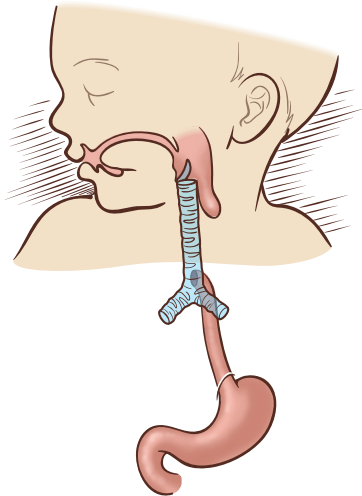
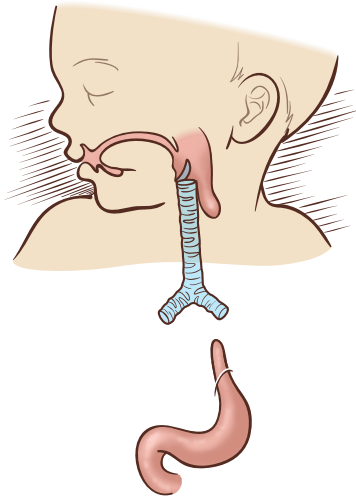


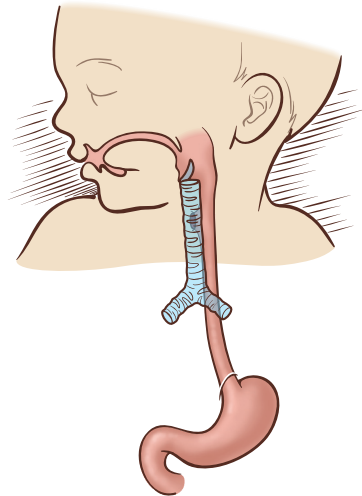
Tracheoesophageal Fistula



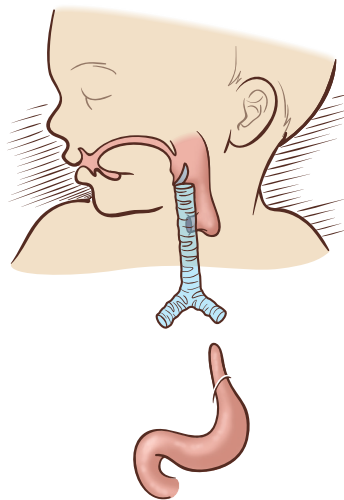
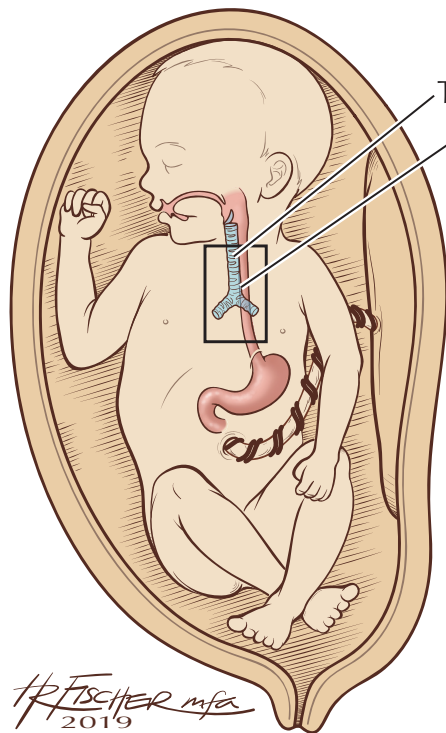
EA with distal TEF (87%)



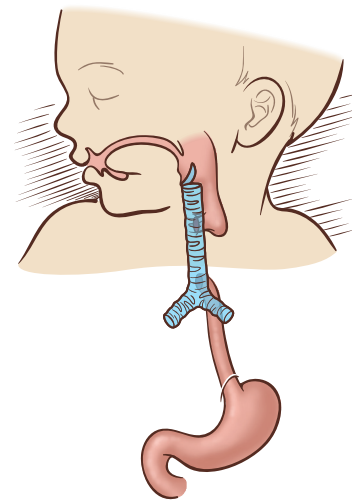
Isolated EA (8%)



Isolated TEF (4%)



EA with proximal TEF (1%)



EA with double TEF (1%)