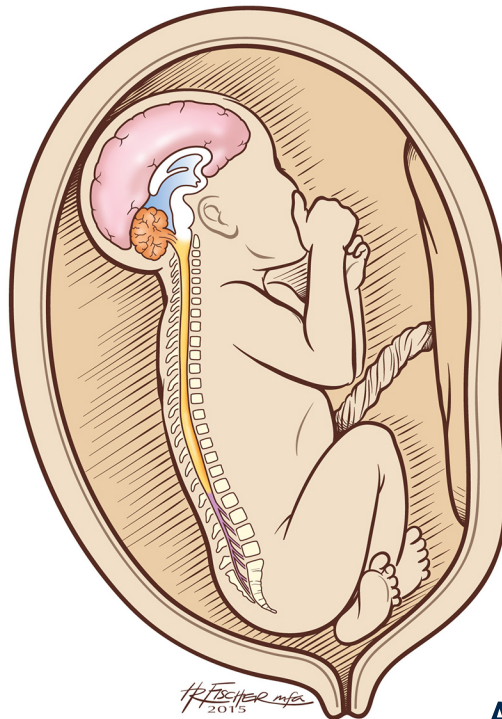
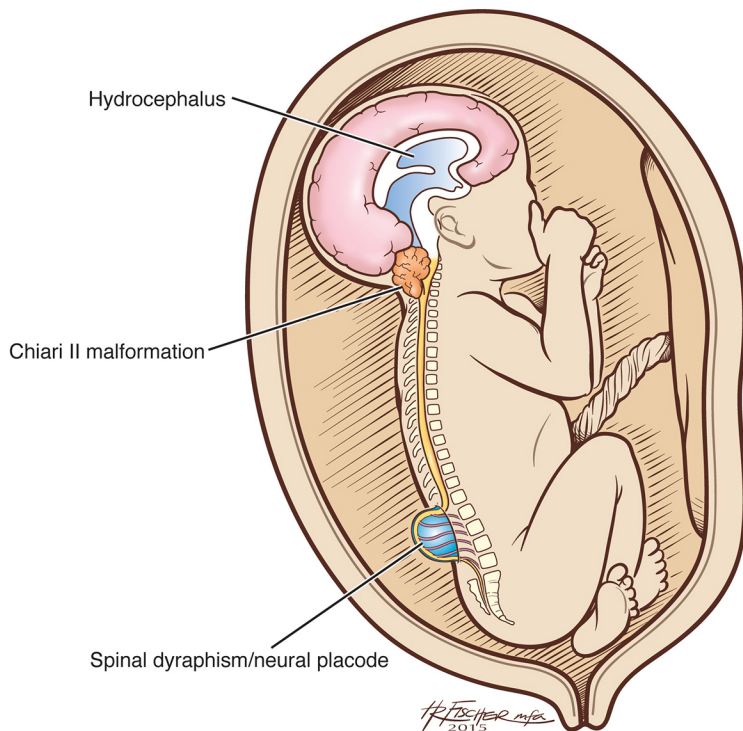


# Fetal Myelomeningocele

## NORMAL FETAL DEVELOPMENT



## FETAL MYELOMENINGOCELE



## AFTER FETAL SURGICAL INTERVENTION

