2-6-03

Urogenital Development II

& Sex Determination

Greg Dressler
Assoc. Professor
Dept. of Pathology

x46490

Dressler@umich.edu

Gross morphological differences between sexes are Not observed until about the 7th week of gestation.

This early period from 0-7 weeks is called the indifferent stage.

However, differences at the genetic and microscopic levels are already Apparent.

Female nuclei contain a Barr body, which is an inactivated X chromosome

Male embryos show gene expression of some Y specific proteins such as SRY, testis determining factor, and the H-Y antigen, a minor histo-compatibility antigen.

Sex determination begins at fertilization

Humans have 46 chromosomes
-22 pairs of autosomes
- 2 sex chromosomes

In general: females are - 46, XX
males are - 46, XY

In mammals, the presence of a Y chromosome determines the male phenotype.

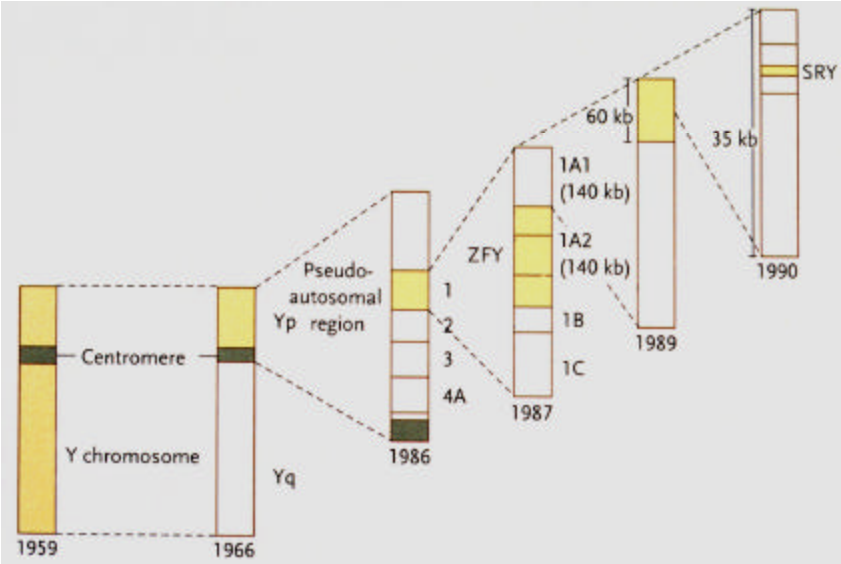

Figure 15-21

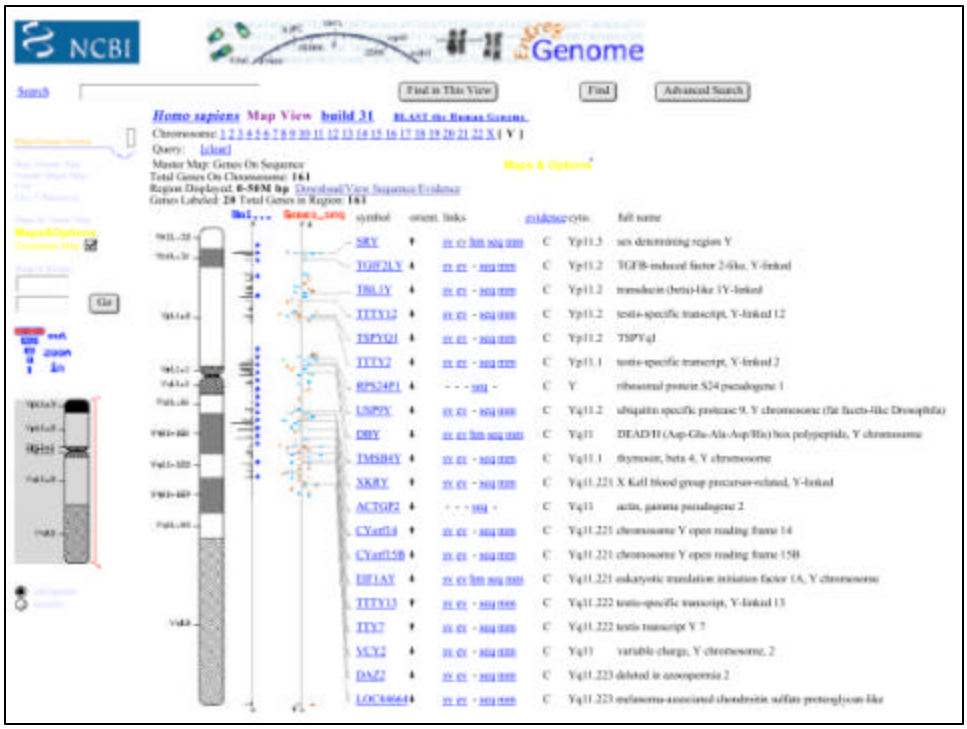

Evidence that SRY is the testis determining factor

SRY is detected in gender reversal:

XX males who have a translocation of the sry region to an X or another chromosome

XY females who have a deletion of the SRY region

In transgenic mice, a 14 kb genomic DNA encoding SRY can transform XX females into phenotypic males.

SRY is expressed in male gonads at the time of sex determination.

SRY encodes a DNA binding protein of the HMG class and is thought to function as a master switch for the regulation of testis specific genes.

Migration of primordial germ cells from the posterior extra-embryonic mesoderm through the mesenteries and into the gonadal ridge

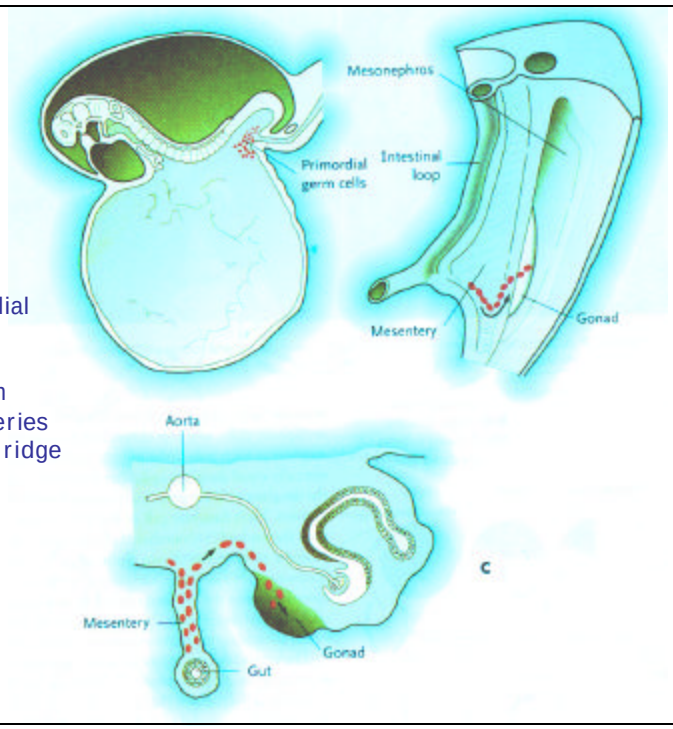

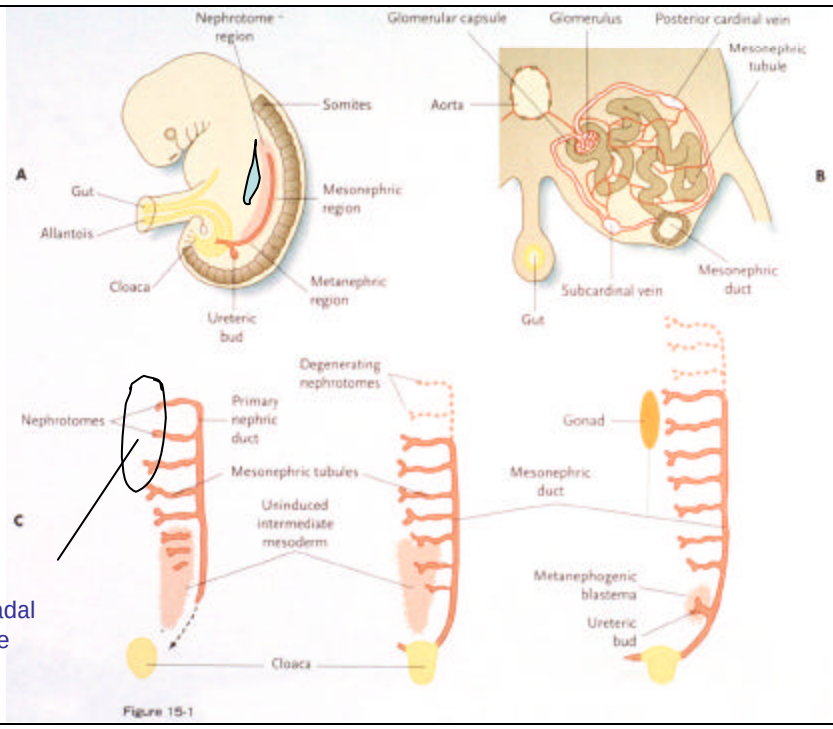

Gonadal ridge

Early stages of sex differentiation, 7 weeks

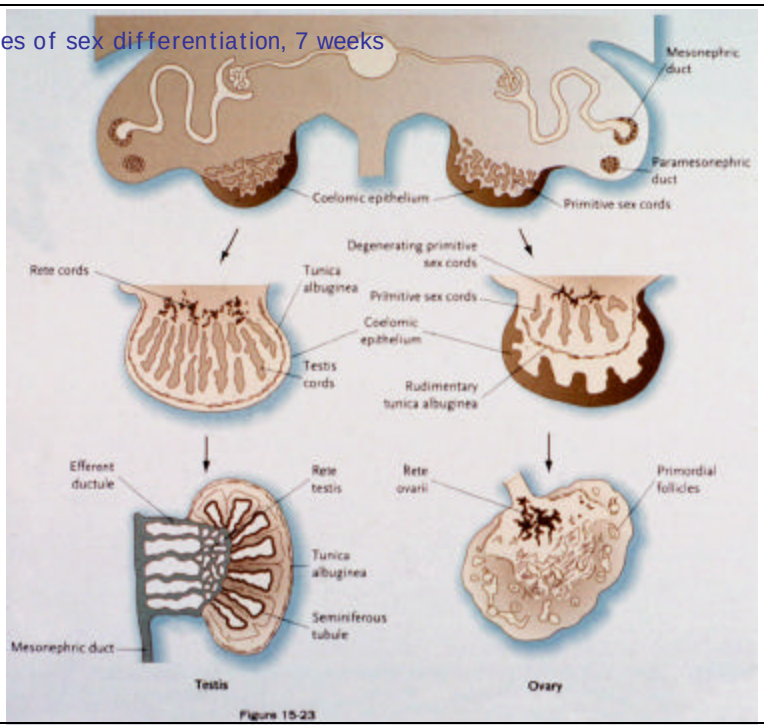

SRY acts on the indifferent gonad to start the process of male sexual development

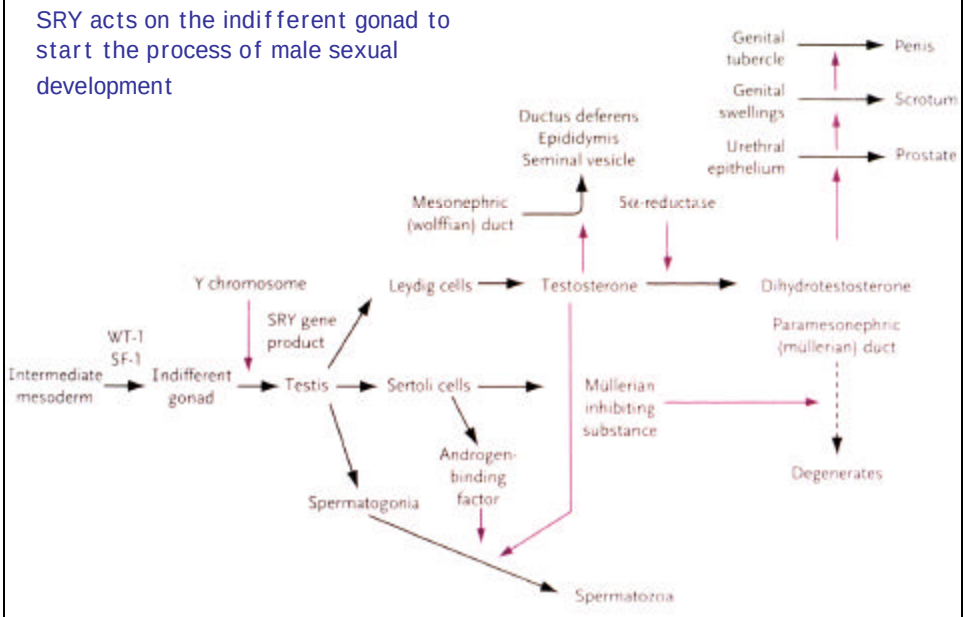

Figure 15-22

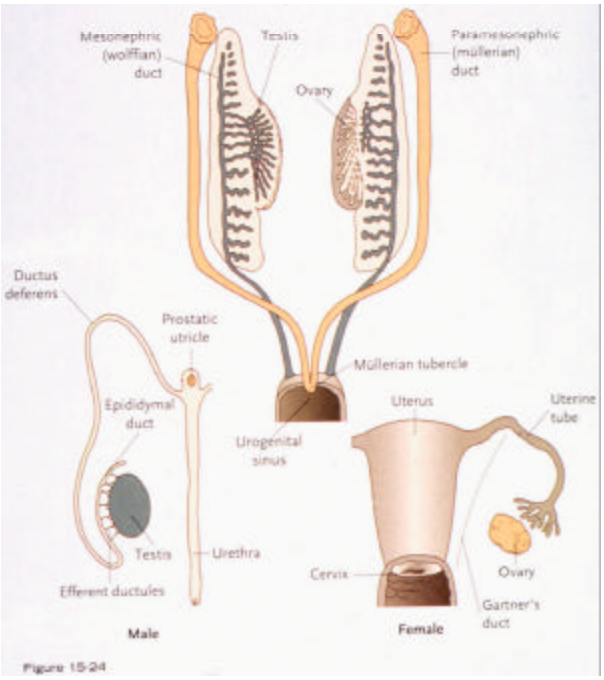

Figure 15-24

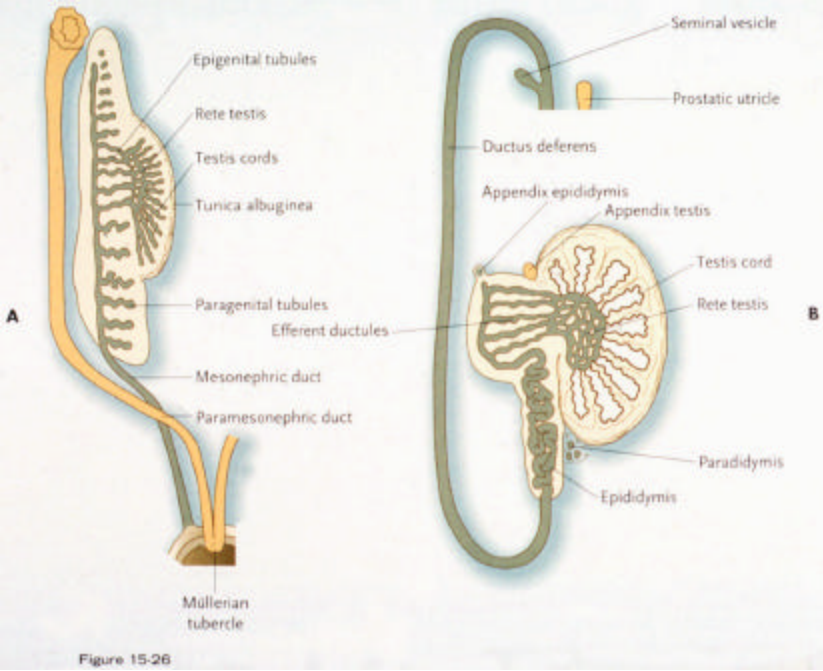

Figure 15-26

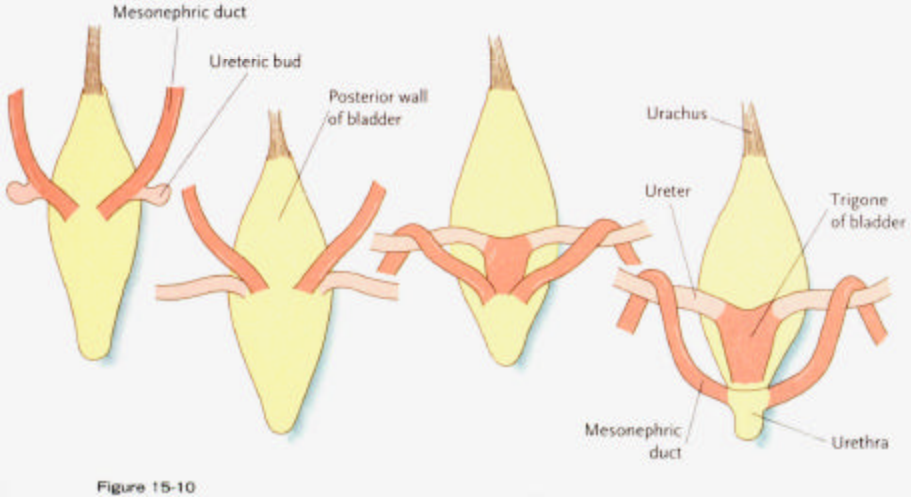

Figure 15-10

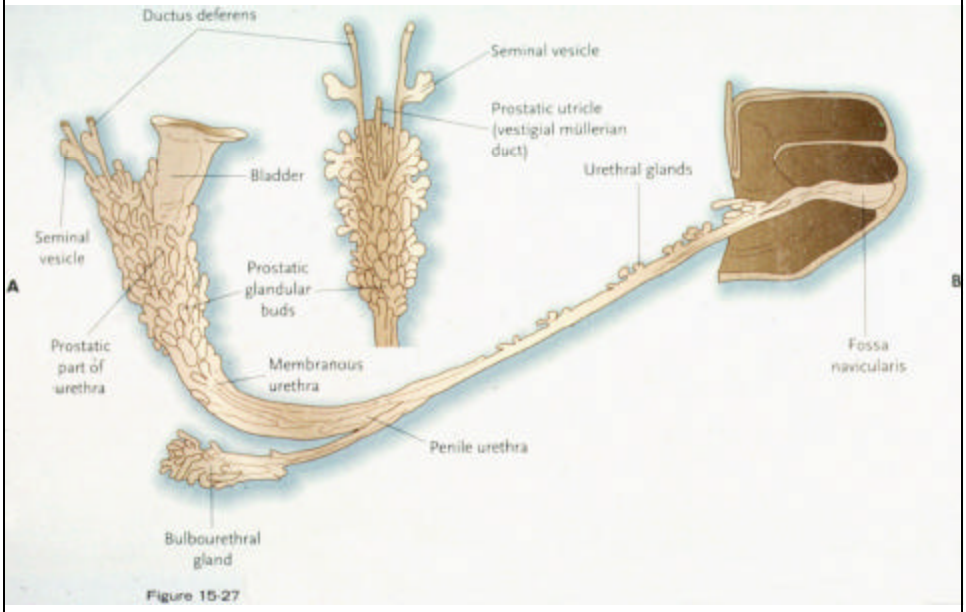

Figure 15-27

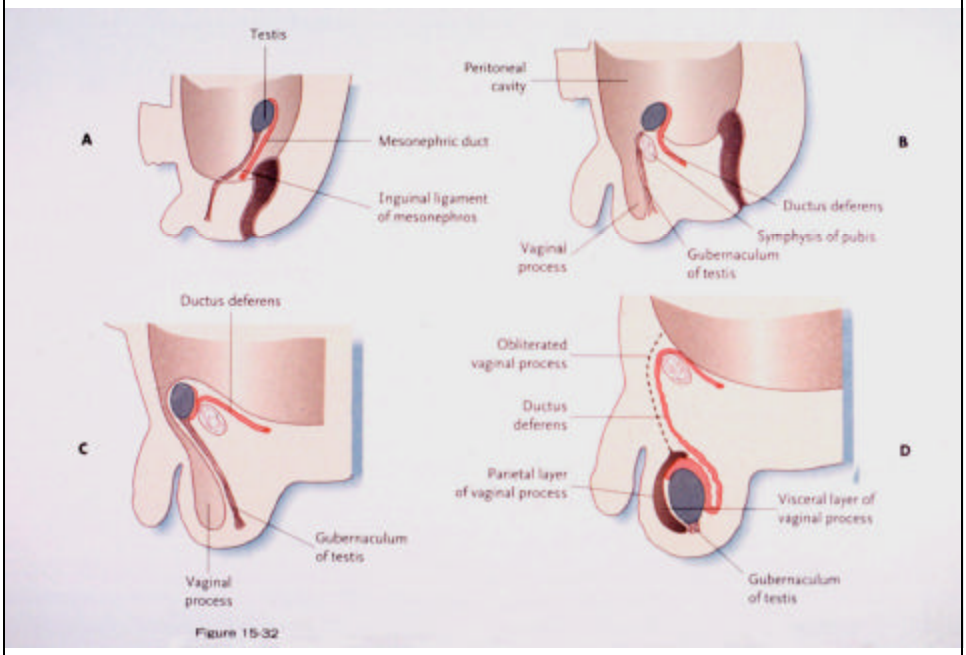

Figure 15-32

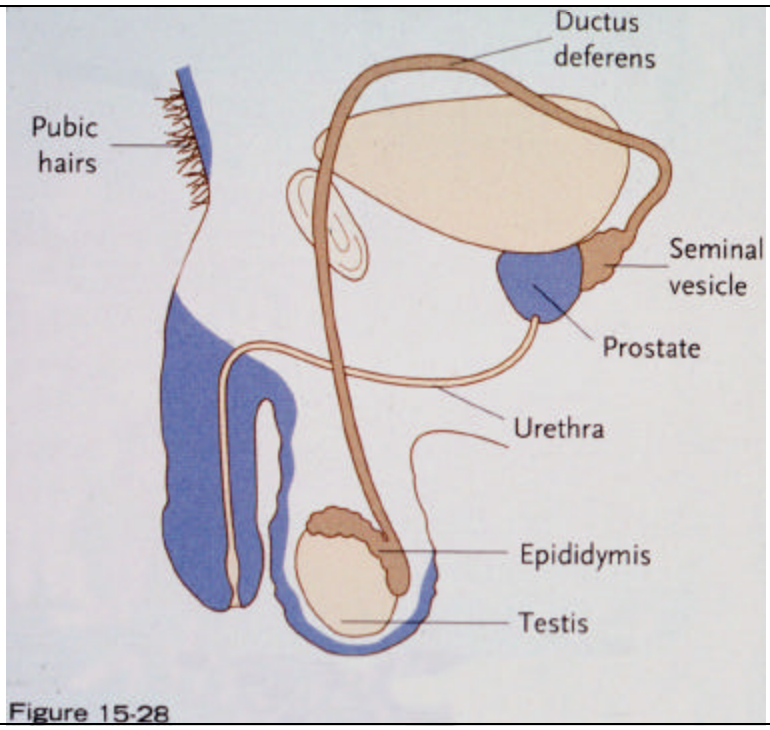

Figure 15-28

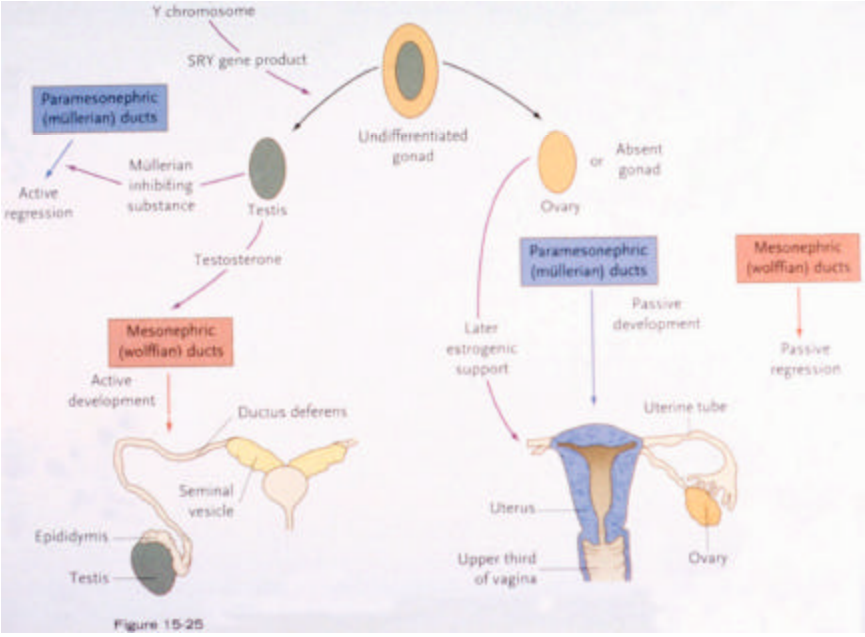

Figure 15-25

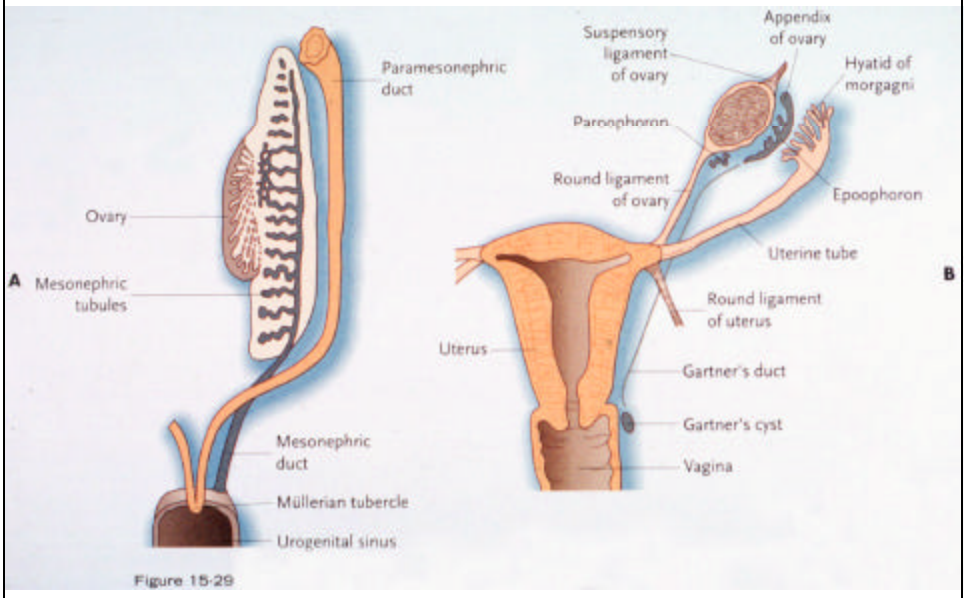

Figure 15-29

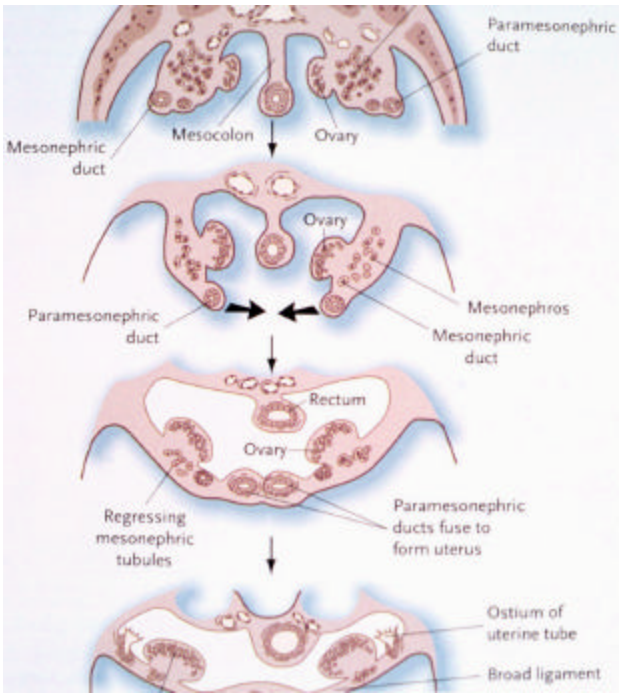
Paramesonephric duct
Mesonephric duct
Mesocolon
Ovary
Ovary
Paramesonephric duct
Mesonephros
Mesonephric duct
Rectum
Ovary
Regressing mesonephric tubules
Paramesonephric ducts fuse to form uterus
Ostium of uterine tube
Broad ligament

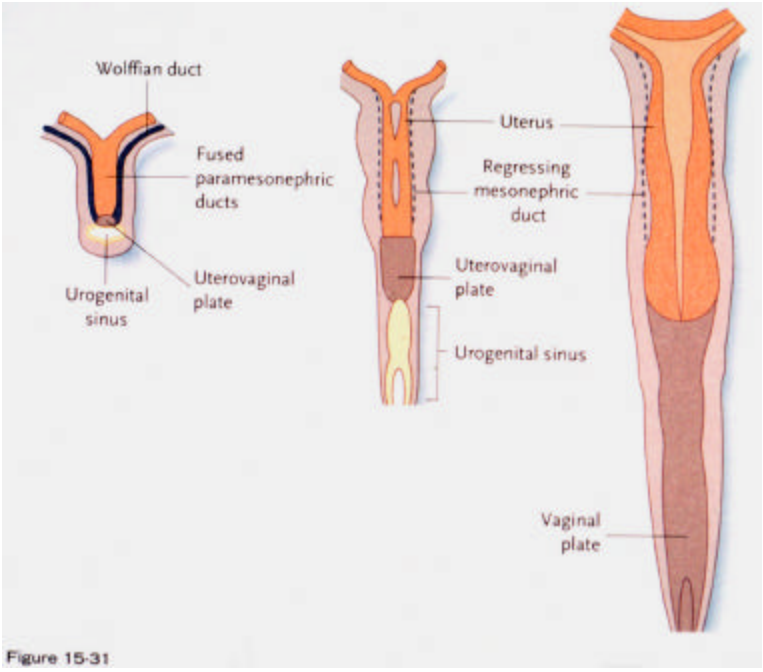
Wolffian duct
Fused paramesonephric ducts
Uterovaginal plate
Urogenital sinus
Uterus
Regressing mesonephric duct
Uterovaginal plate
Urogenital sinus
Vaginal plate

Figure 15-31

Figure 15-33

Development of female External genitalia

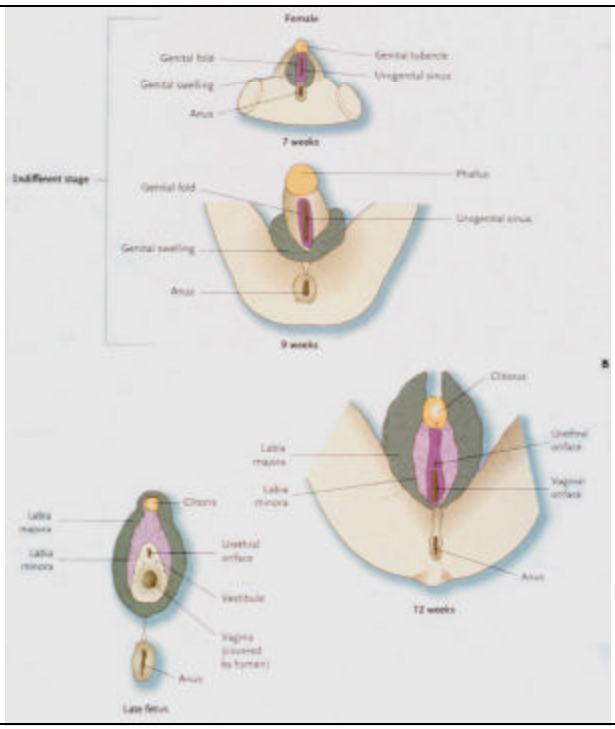

Development of male
External genitalia

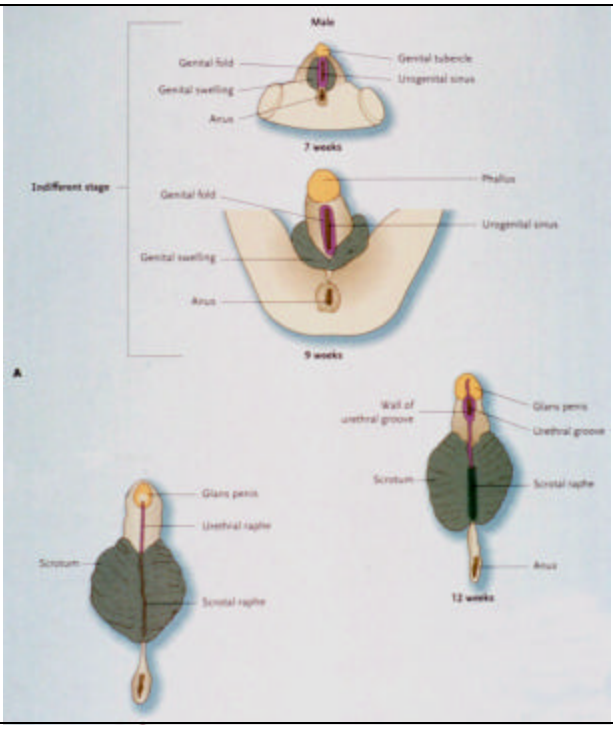

Congenital female abnormalitites

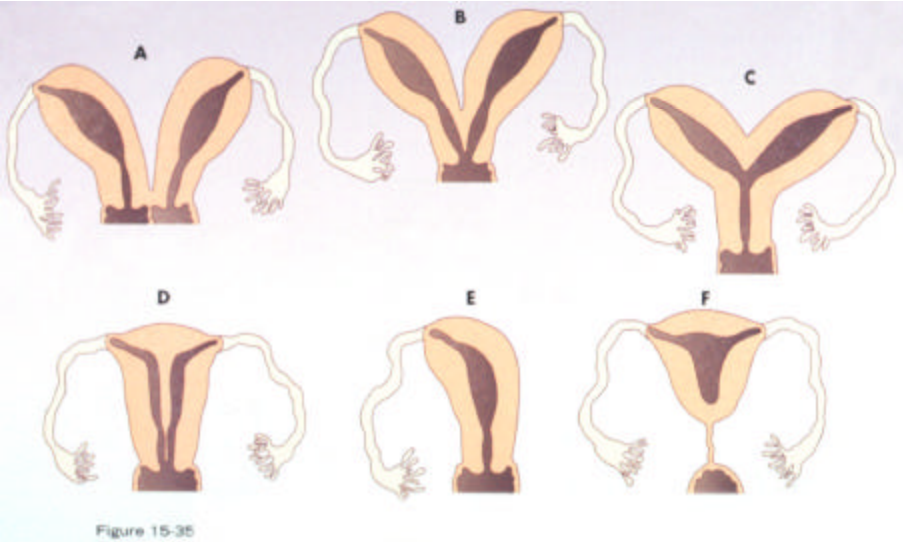

A-double uterus & vagina
B- double uterus, single vagina
C- Bicornuate uterus
D- Septate uterus
E- Unicornuate uterus
F- Atresia of the cervix

Congenital male abnormalitites

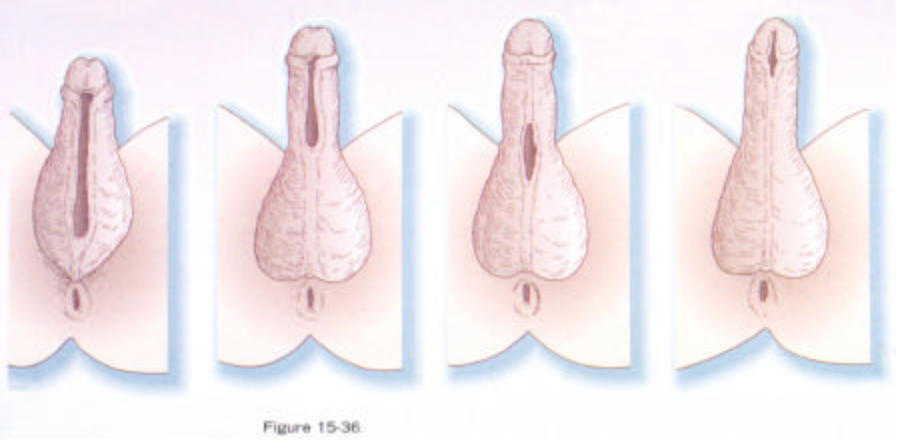

Figure 15-36

Variations in the extent of Hypospadia

Abnormal testicular decent- chryptorchidism results in sterility if testis have not descended within the fist months after birth.

LE 15-1 Homologies in the Male and Female Urogenital Systems

Indifferent structure	Male derivative	Female derivative
Genital ridge	Testis	Ovary
Primordial germ cells	Spermatozoa	Ova
Sex cords	Seminiferous tubules (Sertoli cells)	Follicular cells
Mesonephric tubules	Efferent ductules	Epoophoron
	Paradidymis	Paroophoron
Mesonephric (wolffian) ducts	Appendix of epididymis	Appendix of ovary
	Epididymal duct	Gartner's duct
	Ductus deferens	
	Ejaculatory duct	
Paramesonephric (müllerian) ducts	Appendix of testis	Uterine tubes
	Prostate utricle	Uterus
		Upper vagina
Definitive urogenital sinus (lower part)	Penile urethra	Lower vagina
		Vaginal vestibule
Early urogenital sinus (upper part)	Urinary bladder	Urinary bladder
	Prostatic urethra	Urethra
Genital tubercle	Penis	Clitoris
Genital folds	Floor of penile urethra	Labia minora
Genital swellings	Scrotum	Labia majora

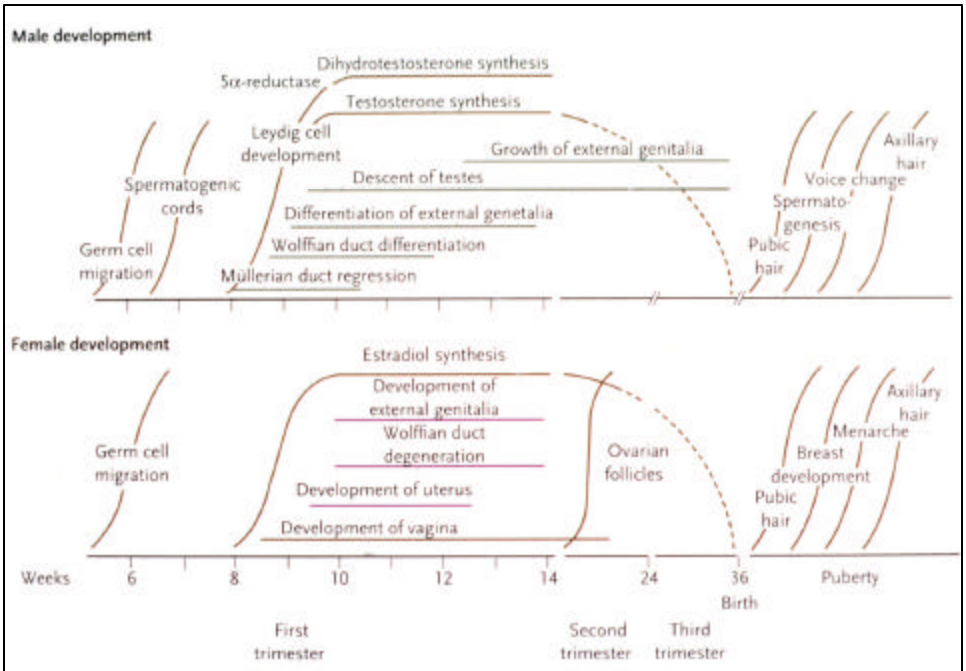

Figure 15-20

Genetic abnormalities of sex determination

Turner's syndrome - gonadal dysgenesis
45,X0 genotype results in degeneration of the promordial germ cells after reaching the gonadal ridge. Gonads fail to differentiate and do not secrete androgens. External genitalia is female but remains infantile.

True Hermaphroditism- generally 46,XX and appear female but have ovotestis, with both spermatagonia and ovarian follicles (very rare and usually raised as female).

Pseudohermaphrodidism- Males are usually 46,XY with insufficient hormone production, phallic hypoplasia, and remnants of the paramesonephric duct present. Femaler are usually 46,XX but produce too much androgenic hormones by the adrenal cortex and exhibit masculinization of external genitalia.

Testicular Feminization- genetically male, 46XY, but phenotypically female. Individuals have internal testis, produce testosterone but are insensistive to androgens due to a receptor mutation.

Fig. 111-8. – Ambiguous genitalia of a male pseudohermaphrodite showing small phallus with hypospadias and opening of urogenital sinus; 46,XY karyotype.

Figure 8–11 The masculinized external genitalia of a female infant with female pseudohermaphroditism caused by congenital virilizing adrenal hyperplasia. The 17-ketosteroid output was elevated. The virilization was caused by excessive androgens produced by the fetal adrenal glands.

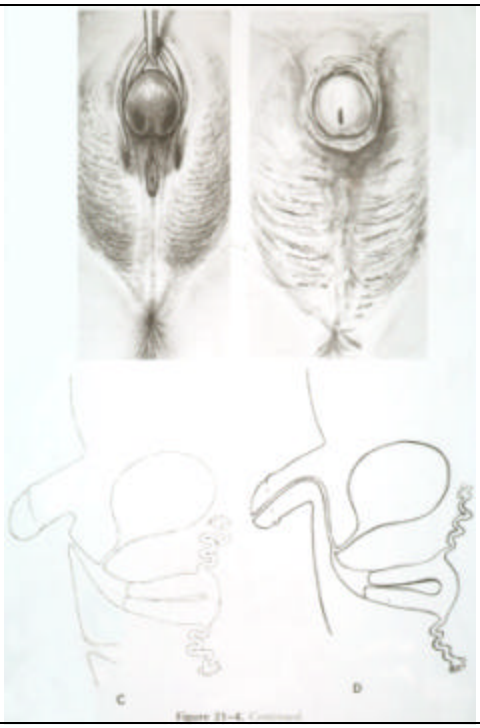
C
D

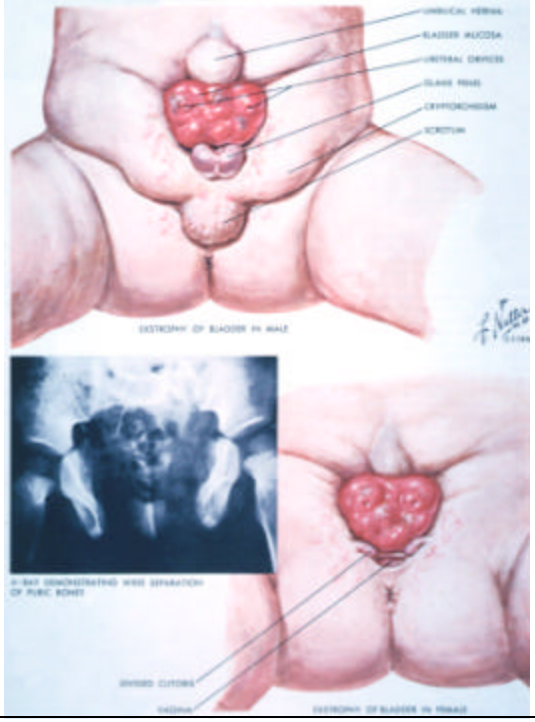
UMBILICAL HERNIA
BLADDER MUCOSA
URETHRAL ORIFICES
GLANS PENIS
CRYPTORCHIDISM
SCROTUM
EXSTROPHY OF BLADDER IN MALE
X-RAY DEMONSTRATING WIDE SEPARATION OF PUBIC BONES
INVERTED CUTISWIS
VAGINA
EXSTROPHY OF BLADDER IN FEMALE

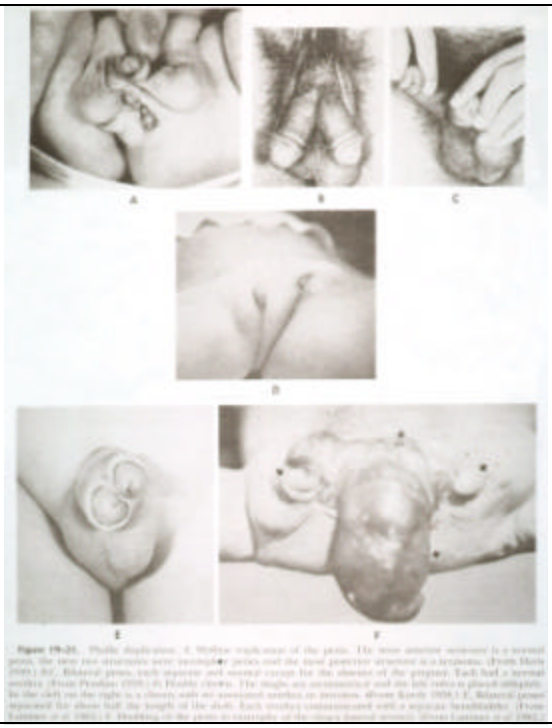

Figure 19-21. Penile duplication. A. Midline staghorn of the penis. The more anterior scrotum is a normal penis, the two two structures were monophyletic penises and the more posterior structure is a scrotum. (From Hurwitz [illegible]). Bilateral penes, each separate and normal except for the absence of the prepuce. Each half a normal urethra (From Perdue [illegible]). Penile clitoris. The single urethra is normal and the left testis is placed ectopically. In the cleft on the right is a clitoris with no associated urethra or vestibule. (From Kiely [illegible]). E. Bilateral penes separated for about half the length of the shaft. Each urethra terminated with a separate hemibladder. (From Kaufman et al [illegible]). F. Doubling of the penis in contrast to the clitoris bifurcated scrotum. (From Lattimer et al [illegible])