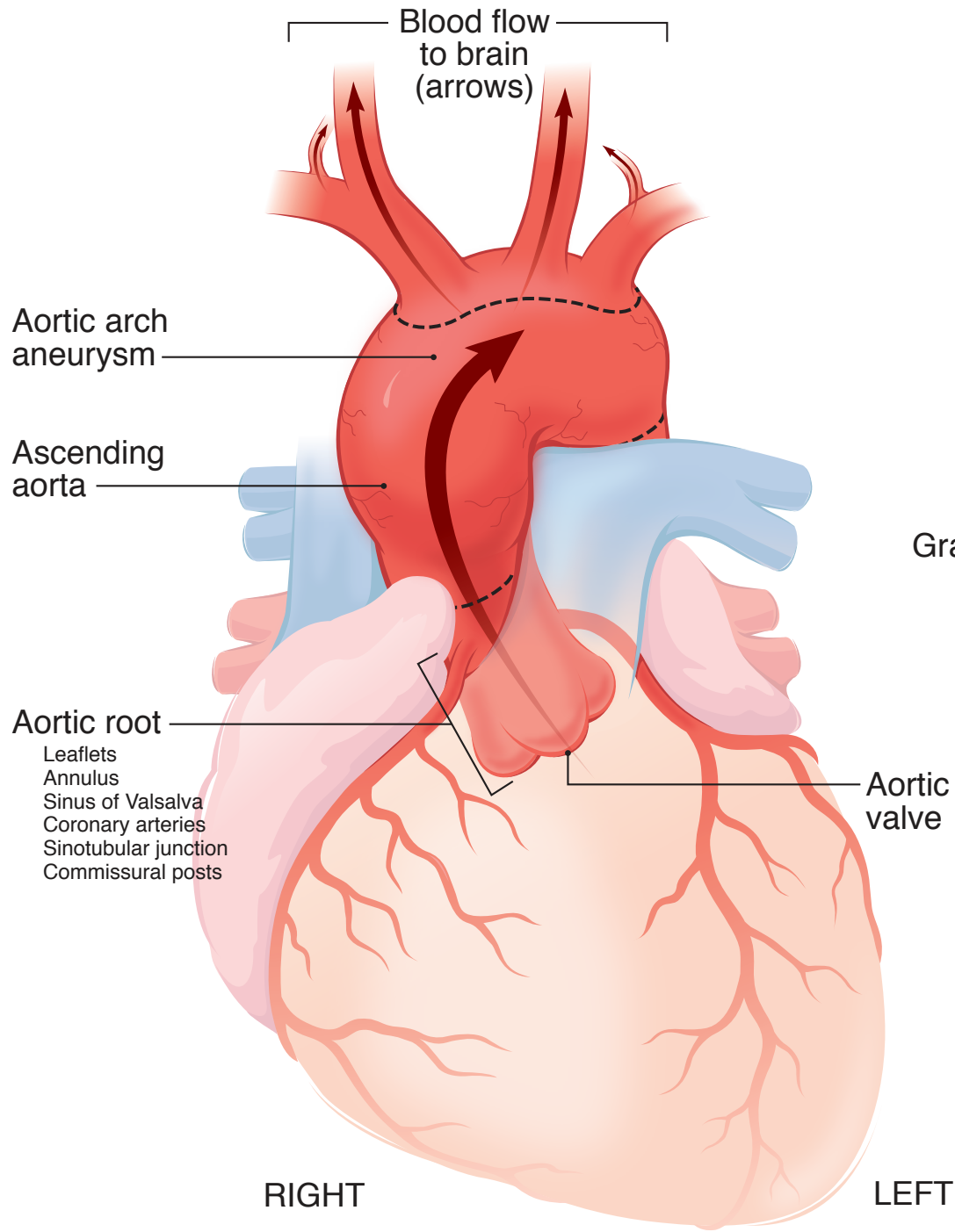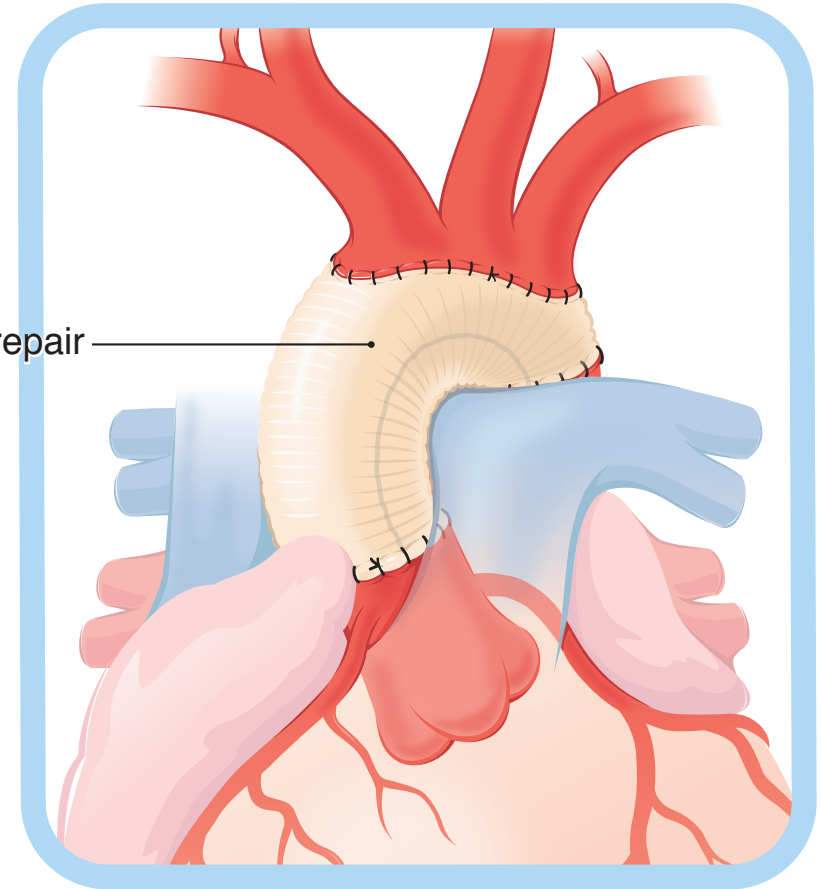


Aortic Arch Aneurysm

After Surgery



L.GAVULIC